

Poxviruses isolated from epidemic Erythromelalgia in China.

By Drs. Z. M. Zheng, J.H. Zhang, J. M. Hu, S. F. Liu, W. P. Zhu
Published in Lancet, Letter to Editor, 1988

Sir, There was an epidemic of erythromelalgia among secondary school students in Hubei, China, in February and March, 1987. Among five schools the average prevalence was 12 (6.4% for males, 28.6% for females; 13.5% for boarders, 22 % for non-resident students). The disease was characterized by burning pain in the toes and soles of the feet and redness, congestion, and edema of the foot; a few patients had fever, palpitations, headache, and joint pain. 60.6% of patients had had a cold before the onset of erythromelalgia and 91.2 % had pharyngitis. We suggested that the pathogenesis of erythromelalgia may be connected with viral infection of the respiratory tract[1,2].

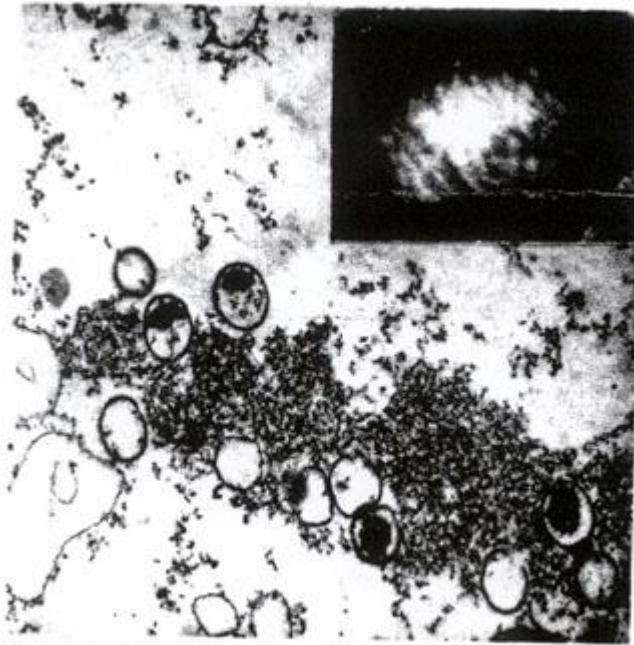
By intraperitoneal inoculation of 1-day-old mice and cell culture techniques Zheng-Zhang virus (ZZV) was isolated from the throat swab of an epidemic erythromelalgia patient in Hanchuan County. The virus can grow in MA104 cells, primary human embryo lung cells, and guinea pig embryo cells resulting in a characteristic cytopathic effect and eosinophilic inclusion bodies in the cytoplasm. Using MA104 cells and primary human embryo lung cells, we isolated another four isolates directly from the throat swabs of four erythromelalgia patients in the one bedroom of Yangjialing Secondary School in Puqi County which is 200 km from Hubei. All five isolates are sensitive to bromodeoxyuridine and resistant to ether. Cytoplasmic inclusion bodies, varying in size with clear margins, were visualized under the electron microscope. Different stages of immature viral particles which are ovoid (average length 375 nm, width 284 nm) were present within the viral inclusion bodies, where viral particles consist of a condensed core and an outer membrane. Vital particles in negative staining samples were ovoid or brick-shaped (239 nm long, 181 nm wide). The surface stripes, the particles were similar to those of vaccinia virus, (figure) [3] Serological data will be reported elsewhere.

It is surprising that a poxvirus should be isolated from patient with erythromelalgia. Human infection with poxviruses is uncommon today, and we know of no report of a relation between poxviruses and erythromelalgia.[4] Are these viruses new poxvirus, or variants of vaccinia or smallpox virus?

Virus Research Institute, Hubei Medical College, Wubah, Hubei,
People's Republic of China

1. Zheng ZM, Liu SF, Hu JM, et al. Survey of epidemic erythromelalgia in Handout, and Puqi of Hubei Province., *J Exp Clin Virol* 1987; 1: 34-39.
2. Zheng ZM, Liu SF, Hu JM, et al. Survey of primary erythromelalgia and analysis its etiology. *Acta Acad Med Hubei* 1987; 8: 195-200.
3. White DO, Fenner Fl. Poxviruses. In: White DO, Fenner FJ, ed. *Medical virology* London: Academic Press, 1986:433-43.
4. Zoppi. M, Zamponi A, Pagni E, Buoncristiano U. A way to understand erythromelalgia. *J Auton New Syst* 1985; 13:85-89.

Sir, There was an epidemic of erythromelalgia among secondary school students in Hubei, China, in February and March, 1987. Among five schools the average prevalence was 12 (6.4% for males, 28.6% for females; 13.5% for boarders, 22 % for non-resident students). The disease was characterized by burning pain in the toes and soles of the feet and redness, congestion, and edema of the foot; a few patients had fever, palpitations, headache, and joint pain. 60.6% of patients had had a cold before the onset of erythromelalgia and 91.2 % had pharyngitis. We suggested that the pathogenesis of erythromelalgia may be connected with viral infection of the respiratory tract[1,2].



Immature viral particles in a cytoplasmic inclusion body ("virus factory").

Some viral particles contain condensed eccentric core (\times about 26 000).
Inset: viral particles in negative staining (\times about 101 000).