

Secondary Erythromelalgia - A Case Report -

Department of Anesthesiology and Pain Medicine, Yonsei University College of Medicine, Seoul,
*National Health Insurance Service Ilsan Hospital, Goyang, Korea

Byoung Chan Kang, MD, Da Jeong Nam, MD*, Eun Kyoung Ahn, MD*,
Duck Mi Yoon, MD, and Joung Goo Cho, MD*

Erythromelalgia is a rare neurovascular pain syndrome characterized by a triad of redness, increased temperature, and burning pain primarily in the extremities. Erythromelalgia can present as a primary or secondary form, and secondary erythromelalgia associated with a myeloproliferative disease such as essential thrombocythemia often responds dramatically to aspirin therapy, as in the present case. Herein, we describe a typical case of a 48-year-old woman with secondary erythromelalgia linked to essential thrombocythemia in the unilateral hand. As this case demonstrates, detecting and visualizing the hyperthermal area through infrared thermography of an erythromelalgic patient can assist in diagnosing the patient, assessing the therapeutic results, and understanding the disease course of erythromelalgia. (Korean J Pain 2013; 26: 299-302)

Key Words:

aspirin, erythromelalgia, infrared thermography, neuropathic pain.

Erythromelalgia is a rare clinical syndrome characterized by a triad of redness, increased temperature, and burning pain primarily in the extremities. The term erythromelalgia, derived from the Greek words for redness and pain in the extremities, was coined in 1878 by Mitchell [1]. It is precipitated by heat, exercise and dependency, and relieved by cold exposure, rest and elevation. The attacks are periodic and can last for various lengths of time ranging from minutes to days.

Erythromelalgia can present as a primary, idiopathic form or secondary to a number of diseases and conditions.

Adults are more commonly involved than children and are more likely to have the secondary form. Secondary erythromelalgia is usually associated with myeloproliferative disorders such as essential thrombocythemia (ET) and polycythemia vera (PV) [2,3].

Herein, we describe a typical case of secondary erythromelalgia that was diagnosed with infrared thermography and treated with aspirin. Although rarely presented, pain clinicians are well advised to be aware of the disease because it can be confused with some other diseases such as CRPS (complex regional pain syndrome), Raynaud's

Received December 21, 2012. Revised January 10, 2013. Accepted January 16, 2013.

Correspondence to: Joung Goo Cho, MD

Department of Anesthesiology and Pain Medicine, National Health Insurance Service Ilsan Hospital, 100 Ilsan-ro, Ilsandong-gu, Goyang 410-719, Korea

Tel: +82-31-900-0640, Fax: +82-31-900-0049, E-mail: anaper@naver.com

© This is an open-access article distributed under the terms of the Creative Commons Attribution Non-Commercial License (<http://creativecommons.org/licenses/by-nc/3.0/>), which permits unrestricted non-commercial use, distribution, and reproduction in any medium, provided the original work is properly cited.

Copyright © The Korean Pain Society, 2013

phenomenon, vasculitis and many other musculoskeletal diseases.

CASE REPORT

A 48-year-old woman visited our pain clinic for 2-year episodes of the right hand and wrist pain with a pain score of 9–10/10 by VNRS (verbal numeric rating scale; 0 with no pain, 10 with maximal pain). She had been to several local clinics. Each time she had been diagnosed with different conditions, such as rheumatic arthritis, Raynaud's phenomenon, and other musculoskeletal diseases. They prescribed painkillers such as acetaminophen, tramadol, pregabalin and even alprazolam along with various physical therapies, but her pain became worse so that she could not even do her house work. The pain started with a sudden onset of "burning" as she described it. It started with her right hand then spread to her wrist. It seemed to worsen whenever she took a bath. Her right hand including all of her fingers seemed red and slightly swollen. No tenderness and warmth were detected. Other parts of her body including the left hand were not involved. Her vital signs including blood pressure were normal and she had no co-existing diseases such as hypertension or diabetes. She recalled no traumatic event happening to the affected area. X-ray findings showed no bony abnormalities. Electromyography and nerve conduction studies of both upper extremities were normal and showed no evidence of peripheral neuropathy. Infrared thermography studies were

performed to assist in understanding the patient's disorder. In the resulting images, the affected areas of her upper extremities appeared red, indicating a higher temperature, while other areas appeared yellow or green, indicating a lower temperature; this visualization also revealed vascular markings in the affected hand. The difference in temperature for the region of interest (ROI) was 2.35°C (35.37°C vs 33.02°C) at the most differentiable area in the third and fourth fingers (Fig. 1).

Laboratory tests were performed including CBC (complete blood count) with differential and platelet counts. Initial red blood cell count was $4.84 \times 10^6/\mu\text{l}$; white blood cell (WBC) count was $8.3 \times 10^3/\mu\text{l}$; hemoglobin level was 13.8 g/dl; hematocrit was 41.7%, and platelet count was $1,131,000/\text{mm}^3$. Prothrombin time (PT) and partial thromboplastin time (aPTT) were 11.3 seconds and 31.2 seconds, respectively. Erythrocyte sedimentation rate (ESR), rheumatoid factor (RF), and antinuclear antibody (ANA) screening data were within the normal range.

We treated her with 500 mg of aspirin per day, and transferred her to a hematologist for further evaluation. She was diagnosed with essential thrombocytosis after a bone marrow biopsy and aspiration study, and chemotherapy was started with anagrelide while continuing to administer a low dose of aspirin (100 mg per day).

A month later, her platelet count measured $340,000/\text{mm}^3$, and her symptoms dramatically disappeared with a pain score of 1/10 (VNRS). Infrared thermography studies also showed a remarkable change. The temperature had

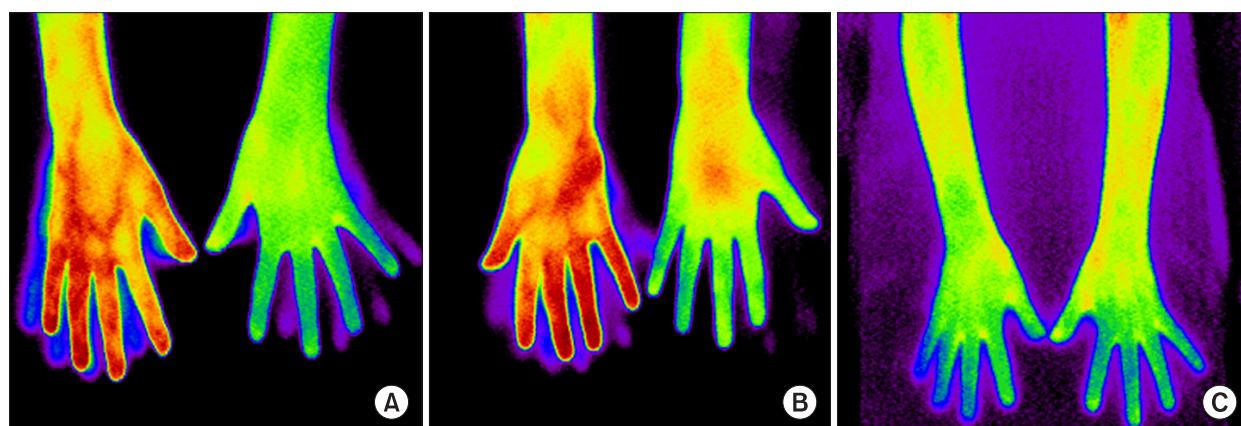


Fig. 1. (A, B) Initial DITI (digital infrared thermal image) shows the higher temperature of the affected area of the right hand specifying vascular markings. (C) DITI a month after aspirin medication and chemotherapy. The temperature in the affected areas decreased showing little color boundary between the affected area and the remaining areas similar to the temperature of the unaffected arm.

decreased in the affected areas, where the color was now yellow; the color boundary between the affected area and the remaining areas was negligible, and the temperature was similar to that of the unaffected arm.

DISCUSSION

Erythromelalgia can be classified as primary or secondary erythromelalgia. Primary erythromelalgia, also known as Weir Mitchell's disease, is an autosomal dominant disorder, and it has recently been accepted as a channelopathy caused by mutations in the voltage-gated sodium channel α -subunit $Na_v 1.7$ encoding gene (*SCN9A*), which is selectively expressed within the nociceptive dorsal root ganglion and sympathetic ganglion neurons. Primary erythromelalgia is the first human disorder that may serve as a model of the association between an ion channelopathy and chronic neuropathic pain [4,5].

Secondary erythromelalgia can result from a number of diseases such as myeloproliferative disorders (i.e. PV, ET), hypercholesterolemia, autoimmune disorder, small fiber peripheral neuropathy, Fabry's disease, mercury poisoning, mushroom poisoning, sciatica and some medications including bromocriptine, verapamil and ticlopidine [6].

Diagnosis is mostly based on the clinical picture because there is no confirmatory diagnostic test. The classic description of erythromelalgia is red, painful, warm hands or feet brought on by warming or hanging the limb downward, and relieved with cooling and elevation of the affected area. Investigating underlying causes such as myeloproliferative disorders is essential. Secondary erythromelalgia often predate myeloproliferative disorders by a median of 2.5 years, thus a blood test should be serially performed once erythromelalgia is diagnosed. Abnormal CBC data such as elevated platelets confirms secondary erythromelalgia [6-8].

Treatment of erythromelalgia is often unsatisfactory because its pathophysiology is not clearly understood. The disease is often unrelenting in nature and not amenable to aspirin therapy. Most patients are subjected to polypharmacy in an attempt to manage pain if it is so severe that it interferes with daily living. Medications such as opioids, gabapentin, lidocaine patches, benzodiazepines and nonsteroidal anti-inflammatory drugs (NSAIDs) are used frequently; however, in most cases, these treatments

either have no proven efficacy or provide only limited relief. Various nerve blocks including epidural blocks and sympathetic blockades have been introduced to treat erythromelalgia unresponsive to non-invasive therapies, resulting in considerable efficacy, but no treatment is consistently effective in the management of erythromelalgic patients. For secondary erythromelalgia, treatment of the underlying disorder consists of the most elementary tactics of management [9,10].

Secondary erythromelalgia is prevalent in 3% to 65% of patients with myeloproliferative disorders, especially polycythemia vera and essential thrombocythosis. Myeloproliferative diseases with thrombocythemia are responsible for 20% of the cases of erythromelalgia [7,8]. Pathological signs presenting with secondary erythromelalgia linked to thrombocythemia include arteriolar intimal proliferation with thrombotic occlusions secondary to platelet aggravation [11]. Some researchers suggest that both hypoxia and hyperemia occur in the disease process with high levels of arteriovenous shunting in the extremities [12].

Secondary erythromelalgia associated with myeloproliferative disease can be dramatically alleviated with high-dose aspirin therapy. The standard treatment is from 325 mg to 650 mg of aspirin per day. Aspirin prevents platelet aggravation through an irreversible inhibition of cyclooxygenase; the effect of a single dose of 500 mg aspirin usually lasts for about three days. This specific long-lasting effect of a single dose of aspirin is pathognomonic and can be used as a diagnostic test in secondary erythromelalgia linked to myeloproliferative disease. A regular low dose of aspirin can also treat erythromelalgia and be a safe method to prevent erythromelalgia [7,13,14].

Infrared thermography can be used in the diagnosis and assessment of therapeutic results for erythromelalgia. Thermography of an erythromelalgic patient may reveal increased temperature in the affected area and the thermal changes can be linked to the relief of symptoms as in our present case. Thompson et al. had reported thermographic findings for a case of primary erythromelalgia with increased skin temperature in the affected area [15]. Primary erythromelalgia often presents as bilateral and symmetric erythro-hyperthermic congestion in the extremities, while secondary aspirin-responsive erythromelalgia linked to myeloproliferative disease has unilateral or bilateral effects but in an asymmetric area. In our

case, the thermography showed a hyperthermal area specifying vascular markings in the unilateral upper extremity, which may suggest an infective or inflammatory disease like vasculitis. However, we could rule out vasculitis or phlebitis due to her normal range in inflammation markers such as her WBC counts and ESR [16,17].

Erythromelalgia can be confused with complex regional pain syndrome (CRPS) because CRPS may also present severe burning pain and/or erythema with thermal change which can be present in thermography. However, these symptoms in patients with CRPS are often unilateral and can be proximal while those in erythromelalgic patients are primarily distal and symmetric if not associated with myeloproliferative diseases. In thermography, CRPS can have increased or decreased thermal areas while the affected area of erythromelalgia is usually increased in temperature. In addition, symptoms triggered by warming of the affected area and relieved by cooling and elevation are less common with CRPS [17].

In this case, we saw a typical case of secondary erythromelalgia associated with thrombocytopenia that was treated successfully with aspirin. In conclusion, pain clinicians should suspect erythromelalgia when seeing a patient with a triad of redness, pain and elevated temperature in the extremities. Infrared thermography can help in diagnosing and understanding the disease course of erythromelalgia by presenting the affected area. The symptom of secondary erythromelalgia with myeloproliferative disorders, such as essential thrombocythemia can be alleviated with aspirin as in this case.

REFERENCES

- Mitchell SW. On a rare vasomotor neurosis of the extremities and on the maladies with which it may be confounded. *Am J Med Sci* 1878; 76: 17–36.
- Novella SP, Hisama FM, Dib-Hajj SD, Waxman SG. A case of inherited erythromelalgia. *Nat Clin Pract Neurol* 2007; 3: 229–34.
- Davis MD, O'Fallon WM, Rogers RS 3rd, Rooke TW. Natural history of erythromelalgia: presentation and outcome in 168 patients. *Arch Dermatol* 2000; 136: 330–6.
- Yang Y, Wang Y, Li S, Xu Z, Li H, Ma L, et al. Mutations in SCN9A, encoding a sodium channel alpha subunit, in patients with primary erythromelalgia. *J Med Genet* 2004; 41: 171–4.
- Waxman SG, Dib-Hajj SD. Erythromelalgia: a hereditary pain syndrome enters the molecular era. *Ann Neurol* 2005; 57: 785–8.
- Naas JE. Secondary erythromelalgia. *J Am Podiatr Med Assoc* 2002; 92: 472–4.
- Kurzrock R, Cohen PR. Erythromelalgia: review of clinical characteristics and pathophysiology. *Am J Med* 1991; 91: 416–22.
- Hart JJ. Painful, swollen, and erythematous hands and feet. *Arthritis Rheum* 1996; 39: 1761–2.
- Davis MD, Rooke T. Erythromelalgia. *Curr Treat Options Cardiovasc Med* 2006; 8: 153–65.
- Bang YJ, Yeo JS, Kim SO, Park YH. Sympathetic block for treating primary erythromelalgia. *Korean J Pain* 2010; 23: 55–9.
- Michiels JJ, van Joost T. Erythromelalgia and thrombocytopenia: a causal relation. *J Am Acad Dermatol* 1990; 22: 107–11.
- Kalgaard OM, Seem E, Kvernebo K. Erythromelalgia: a clinical study of 87 cases. *J Intern Med* 1997; 242: 191–7.
- van Genderen PJ, Michiels JJ. Erythromelalgia: a pathognomonic microvascular thrombotic complication in essential thrombocythemia and polycythemia vera. *Semin Thromb Hemost* 1997; 23: 357–63.
- Preston FE. Aspirin, prostaglandins, and peripheral gangrene. *Am J Med* 1983; 74: 55–60.
- Thompson GH, Hahn G, Rang M. Erythromelalgia. *Clin Orthop Relat Res* 1979; (144): 249–54.
- Michiels JJ. Platelet-mediated microvascular inflammation and thrombosis in thrombocytopenia vera: a distinct aspirin-responsive arterial thrombophilia, which transforms into a bleeding diathesis at increasing platelet counts. *Pathol Biol (Paris)* 2003; 51: 167–75.
- Ring EF, Ammer K. Infrared thermal imaging in medicine. *Physiol Meas* 2012; 33: R33–46.