

## Defining a Treatable Cause of Erythromelalgia: Acute Adolescent Autoimmune Small-Fiber Axonopathy

Joshua Paticoff, MD\*

Assia Valovska, MD\*

Srdjan S. Nedeljkovic, MD\*

Anne Louise Oaklander, MD,  
PhD†

Conditions described as “erythromelalgia” and “erythermalgia” are being formally specified by etiological diagnoses that enable the use of disease-modifying as well as symptomatic treatments. We describe an otherwise healthy 20-year-old man with acute-onset erythromelalgia. Severe bilateral distal limb pain and vasodilation persisted despite the use of many antihyperalgesics. Pathological examination of cutaneous nerve endings revealed severe small-fiber predominant axonopathy. Treatment of his apparent autoimmune polyneuropathy with high dose corticosteroids, 4 days of lidocaine infusion, and a prednisone taper cured him. Similarities to other cases allowed us to tentatively characterize a new treatable cause of erythromelalgia; acute adolescent autoimmune small-fiber axonopathy. In this report we evaluate various options for diagnosis and treatment.

(*Anesth Analg* 2007;104:438–41)

**E**rythromelalgia (Gr: red, painful limb) (1) is a symptom complex of distal limb edema and burning pain that can be constant or paroxysmal, acute and/or severe, or chronic and indolent. Severely affected patients immerse their limbs in cold water to reduce their pain (2). Despite increased total limb perfusion there is paradoxical tissue ischemia from precapillary arteriovenous shunting (3). Both ischemia and neuralgia contribute to the pain. Microneurography has identified low conduction velocities and spontaneous activity and sensitization of mechano-insensitive C-fibers (4).

Bilateral erythromelalgia is commonly associated with three etiologies. Mutations in the Na<sub>v</sub>1.7 sodium channel-subunit of sensory and sympathetic neurons (5) have been identified in childhood onset familial (6,7) and sporadic erythromelalgia (6,8). Myeloproliferative disorders infrequently cause erythromelalgia through undefined mechanisms, as do various small-fiber axonopathy (SfA) (9–12). We describe the successful treatment of a

20-year-old with acute erythromelalgia, apparently caused by autoimmune SfA. Similarities to other cases allowed us to tentatively characterize a new syndrome: acute adolescent erythromelalgic small-fiber axonopathy.

### CASE REPORT

A healthy 20-year-old man vacationing in Bermuda sprained an ankle. Within 5 h, redness and pain “like broken glass running through my veins” developed in his hands and feet. His pain worsened when he showered with warm water and improved with cold water immersion. His medical history revealed only childhood pneumonia and treatment for anxiety and depression. He was a high level lacrosse competitor who occasionally used alcohol, but no tobacco or illicit drugs. He had no family history of neurological disorders. While flying home 2 days later he held ice in his hands and placed it under his bare feet for pain relief. He went immediately to a local emergency department (ED). Gabapentin and hydrocodone/acetaminophen were prescribed, but were ineffective. Two days later he came to a Boston ED where testing, including lumbar puncture, was performed (Table 1). Gabapentin was increased, and mannitol prescribed for possible ciguatera (13). Because he was no better the next day, he came to Brigham and Women’s ED. Examination revealed hypertension and red swollen feet, which he had submerged in cold water. Hydromorphone was prescribed and his gabapentin increased. The next day he returned and was admitted. A neurologist’s examination was reported as entirely normal. Cardiac evaluation revealed no cause for chronic tachycardia (90–150) and hypertension (160–200/80–110 mm Hg) that required prolonged  $\beta$ -blockade. Many pain medications were ineffective (Table 2). Two trials of IV lidocaine 50 mg/h for 4 h transiently improved his pain, and he was discharged with pregabalin 400 mg, amitriptyline 25 mg, and mexiletine 600 mg daily, but his pain remained intolerable and so he was readmitted 4 days later. Pregabalin was increased to 600

From the \*Department of Anesthesiology, Perioperative and Pain Medicine, Brigham and Women’s Hospital; and †Departments of Neurology and Pathology (Neuropathology), Massachusetts General Hospital, Harvard Medical School, Boston, Massachusetts.

Accepted for publication October 17, 2006.

Supported by Public Health Service Grant NINDS R01NS42866.

Nedeljkovic, MD and Anne Louise Oaklander, MD, PhD contributed equally to this work.

Address for correspondence and reprint requests to Srdjan S. Nedeljkovic, MD, Pain Management Center, Brigham and Women’s Hospital, 850 Boylston St., Chestnut Hill, MA 02467. Address e-mail to [srdjan@zeus.bwh.harvard.edu](mailto: srdjan@zeus.bwh.harvard.edu).

Copyright © 2007 International Anesthesia Research Society  
DOI: 10.1213/01.ane.0000252965.83347.25

**Table 1.** Tests with Normal Results

Routine tests	CBC (WBC 8.7, Hgb 16.5, Plt 275), electrolytes, coagulation parameters, liver and kidney function, TSH (2.35), urinalysis, toxicology screen, HgbA1c
Tests for infection	Lyme, gonorrhea, chlamydia, syphilis, HIV, parvovirus B19
Neurological tests	LP yielded clear, colorless fluid with normal pressure, protein 33, glucose 60, 0 RBC, 2 WBC; 100% lymphs. VDRL culture, serum folate (11.7), vitamin B12 (365), $\alpha$ -galactosidase levels (for Fabry disease), urine mercury and arsenic
Rheumatological tests	ESR (6, 5, 13), SPEP, IPEP, UPEP, C-reactive protein, ANA, RHF
Radiological tests	Radiographs of sprained ankle, CT, and MRI of his brain

CBC = Complete blood cell count; WBC = white blood cell count; Hgb = hemoglobin; Plt = platelet; TSH = thyroid stimulating hormone; LP = lumbar puncture; RBC = red blood cell count; VDRL = venereal disease research laboratory test; ESR = erythrocyte sedimentation rate; SPEP = serum protein electrophoresis; IPEP = immune globulin protein electrophoresis (immunoelectrophoresis); UPEP = urine protein electrophoresis.

ANA = antinuclear antibody; RHF = rheumatoid factor; CT = computed tomography scan; MRI = magnetic resonance scan; HIV = human immunodeficiency virus.

**Table 2.** Pain Management Treatments Implemented

	Treatments tried
Antiinflammatory	Ibuprofen, aspirin, naproxyn, ketorolac
Antidepressant	Amitriptyline, venlafaxine, bupropion, duloxetine
Antiepileptic	Gabapentin, pregabalin, phenytoin, divalproex, lamotrigine
Opioid	Tramadol, oxycodone, hydromorphone, morphine
Topical treatment	Aquaphor, lidocaine ointment, capsaicin, lidocaine patch 5%
Miscellaneous	Acetaminophen, flexeril, mexiletine, mannitol infusion, clonidine patches to dorsum of hands, IV ketamine lorazepam, esomeprozole, lovenox, clonazepam, various sleep aids and laxatives, IV methylprednisolone, IV lidocaine
Nonpharmacologic	Acupuncture, hypnosis

mg daily, amitriptyline was stopped, and venlafaxine and phenytoin were instituted.

After discharge, acupuncture was found ineffective. His foot pain waned (attributed by the patient to total sensory loss), but increasing hand pain prompted a third admission for unsuccessful trials of IV ketamine and clonidine patches (Fig. 1A). An interview with a toxicologist established that he had not eaten any potentially ciguatoxic large fish (13). Nerve conduction studies (NCS) performed 1 mo after onset showed normal compound motor potentials, and normal (superficial peroneal), borderline (sural), and slightly prolonged (median) distal sensory latencies, which was thought to possibly be due to his chilled limbs. Sensory amplitudes were normal except for mild right median reduction. He could not tolerate electromyography (EMG). Punch skin biopsies from his distal leg (14) showed erythrocyte extravasation, mast cells, fluid in the dermis, and no amyloid birefringence. PGP9.5 immunolabeling of axons was nearly absent, indicating severe distal sensory axonopathy. Skin biopsies from other patients that were processed simultaneously labeled normally. Small-fiber predominant axonopathy was diagnosed and attributed to autoimmune causes.

Methylprednisolone 1 g daily was administered IV for 4 days. His pain scores, 8/10, decreased within hours to 5/10. On day 4, continuous lidocaine infusions were initiated at 0.5 mg/min, and increased by 0.5 mg/min daily to 2.5 mg/min. His plasma levels increased from <1.0 to 2.5  $\mu$ g/mL without adverse effects. His pain scores remained 4–5/10 but ambulation increased. He was discharged using prednisone 90 mg daily, pregabalin 900 mg, mexiletine 150 mg, metoprolol 150 mg, venlafaxine XR 75 mg, duloxetine 60

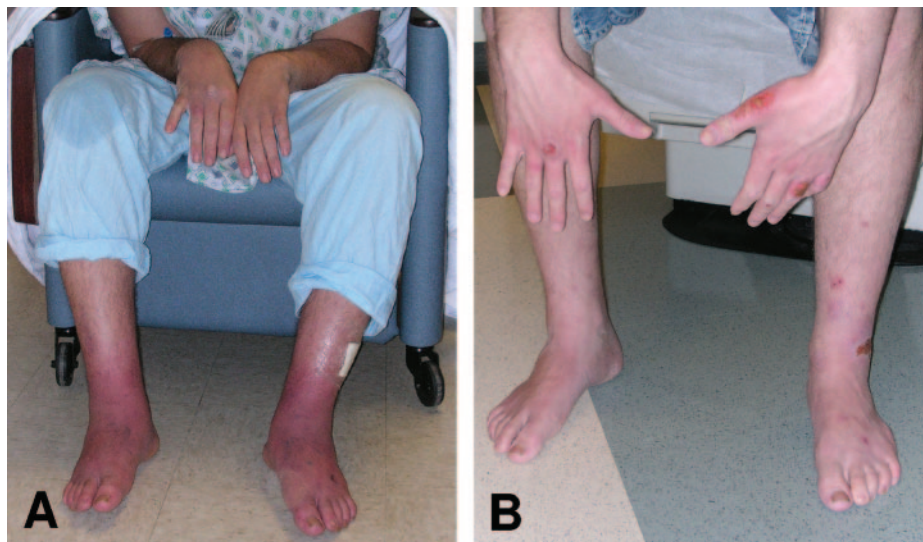
mg, and clonazepam 3 mg. He developed an infected ankle ulcer from scratching the neuropathic itch in his desensate skin (Fig. 1B).

Prednisone was tapered over 6 wk. His vital signs normalized, though a 23-kg weight loss persisted. Leg atrophy and weakness resolved quickly with rehabilitation, but neurogenic hand weakness with muscle atrophy and mild contractures lingered (Fig. 1B). At discharge he could not write, but at 9 mo post-onset his only residual difficulty was in fastening clothing. Complete sensory loss of his palms and soles improved. At 4 mo post-onset, autonomic testing revealed four limb sweating loss and normal heart rate variability. At 13 mo post-onset he remained symptom-free without medication.

## DISCUSSION

Our patient's symptoms, examination, EMG/NCS, skin biopsy, and sweat testing established SfA as the cause of his erythromelalgia. SfA is difficult to detect and often remains undiagnosed. EMG/NCS is insensitive to small-fibers and so remains normal or nearly so in erythromelalgia (15,16) and SfA (17). Neurodiagnostic skin biopsy is a sensitive test (14) that was diagnostic in four of five other similar cases (15,16). Light microscopic evaluation of sural nerves is insensitive because small fibers are invisible without electron microscopy (15). Severely reduced sweating in our patient established that his SfA affected cholinergic autonomic axons. Quantitative sweat testing, diagnostic in 75% of SfA patients (18), appears promising for erythromelalgia diagnosis. Tests of adrenergic axons were normal in our patient as in many SfA patients (18). Quantitative sensory testing, often abnormal in SfA (15), is subjective and nonspecific.

Because we found no other causes of SfA (Table 1), and because skin biopsy revealed mastocytosis, isolated autoimmune polyneuropathy was diagnosed and validated by successful immunosuppression. Rheumatologists did not find vasculitis or extra-neural involvement. Guillain-Barré syndrome is a better known isolated autoimmune polyneuropathy that affects myelinated motor and rarely sensory fibers (19). Preliminary evidence suggests that the inflammatory infiltrates of Guillain-Barré syndrome are absent in autoimmune SfA (15). Sparse mast cells are common. Our patient's cerebrospinal fluid had normal cells and protein but in another study, six of six older patients with nonerythromelalgia SfA had high protein without cells (20).



**Figure 1.** A. Photo of patient on December 5, 2005, 5 wk post-onset and immediately before corticosteroid treatment. Edema and erythema are worse in his feet, although they were largely insensate and his hand pain was then worse than his foot pain. He removed his hands from ice water to be photographed as shown by the water dripping on his right knee. There are early skin erosions on the dorsum of his right hand and left foot. B. Photo of patient on January 6, 2006 during outpatient prednisone taper. Note the resolution of distal limb edema and erythema but worsening of skin ulcers. His left first dorsal interosseous muscle had neurogenic atrophy.

Several immunosuppressants have been tried in autoimmune SfA. Cyclophosphamide  $1 \text{ mg} \cdot \text{kg}^{-1} \cdot \text{d}^{-1}$  (16) and IV immunoglobulin ( $2 \text{ g} \cdot \text{kg}^{-1} \cdot \text{d}^{-1} \times 5$ ) (15) were ineffective in a few steroid-responsive patients. Plasmapheresis is untested for autoimmune SfA. Prednisone  $1 \text{ mg} \cdot \text{kg}^{-1} \cdot \text{d}^{-1}$  has dramatically improved some patients' condition (16, Oaklander, unpublished data) but not others (20,21). One prednisone-responder had added benefit from methylprednisolone  $1 \text{ g/d}$  during flare-ups (16). Pain management is notoriously difficult in erythromelalgia (Table 2). Here, most medicines were ineffective but pregabalin helped during recovery. Tricyclics should have been tried for a longer period. Continuous systemic lidocaine followed by mexiletine reduced his pain and increased his activity as it has in other erythromelalgia patients (22). Untried treatments include sodium nitroprusside (21,23), prostacyclin (24), and topical amitriptyline/ketamine (25). Epidural morphine/bupivacaine has helped acute hand-predominant erythromelalgia (21).

Severe acute erythromelalgia has complications which include significant weight loss (15,21). Because malnutrition can worsen polyneuropathy, supplements may be indicated. Our patient and others (23) had long-lasting hypertension and tachycardia consistent with autonomic neuropathy. Some patients develop distal limb ulcers from hypoxia (6,23). SfA probably contributes by thinning the skin (26). SfA can cause neuropathic itch in desensate skin which predisposes to self-injury (Fig. 1B) (27). Corticosteroids presumably exacerbate infection risk. As with diabetes, vascular and neurologic abnormalities can combine to cause ulcers, infection, sepsis, and amputation (2,28).

Age may influence the risk for developing erythromelalgia symptoms. The two other well-documented cases of erythromelalgia acute autoimmune small-fiber axonopathy are also in adolescents (15) as are other possible cases (21,23). Reported acute autoimmune small-fiber axonopathy patients without erythromelalgia phenotype were older (ages 59, 55, 46) (15,16). We conclude that adolescents with acute erythromelalgia should be evaluated for autoimmune SfA and possible immunosuppression with corticosteroids and pain management with systemic lidocaine. It may be useful to investigate whether childhood onset genetic cases and myeloproliferative cases in older adults also involve SfA.

#### ACKNOWLEDGMENTS

The authors thank the contributions of the many people who cared for this patient, and particularly acknowledge the diagnostic contributions of Anthony Amato, Vice Chairman, Department of Neurology, Brigham and Women's Hospital, and Frederick W. Berman, Director of the Center for Research on Occupational and Environmental Toxicology at OR Health and Science University. The authors also appreciate their patient's assistance with this report.

#### REFERENCES

- Mitchell SW. On a rare vaso-motor neurosis of the extremities, and on the maladies with which it may be confounded. *Am J Med Sci* 1878;76:2–36.
- Kalgaard OM, Seem E, Kvernebo K. Erythromelalgia: a clinical study of 87 cases. *J Intern Med* 1997;242:191–7.
- Mork C, Kalgaard OM, Kvernebo K. Impaired neurogenic control of skin perfusion in erythromelalgia. *J Invest Dermatol* 2002;118:699–703.
- Orstavik K, Weidner C, Schmidt R, et al. Pathological C-fibres in patients with a chronic painful condition. *Brain* 2003;126:567–78.

5. Klugbauer N, Lacinova L, Flockerzi V, Hofmann F. Structure and functional expression of a new member of the tetrodotoxin-sensitive voltage-activated sodium channel family from human neuroendocrine cells. *EMBO J* 1995;14:1084-90.
6. Yang Y, Wang Y, Li S, et al. Mutations in SCN9A, encoding a sodium channel alpha subunit, in patients with primary erythromelgia. *J Med Genet* 2004;41:171-4.
7. Dib-Hajj SD, Rush AM, Cummins TR, et al. Gain-of-function mutation in Na<sub>v</sub>1.7 in familial erythromelgia induces bursting of sensory neurons. *Brain* 2005;128:1847-54.
8. Han C, Rush AM, Dib-Hajj SD, et al. Sporadic onset of erythromelgia: a gain-of-function mutation in Na<sub>v</sub>1.7. *Ann Neurol* 2006;59:553-8.
9. Davis MD, Sandroni P, Rooke TW, Low PA. Erythromelgia: vasculopathy, neuropathy, or both? A prospective study of vascular and neurophysiologic studies in erythromelgia. *Arch Dermatol* 2003;139:1337-43.
10. Oaklander AL. Erythromelgia: small-fiber neuropathy by any other name? *Pediatrics* 2005;116:293-4.
11. Mork C, Kalgaard OM, Kvernebo K. Erythromelgia as a paraneoplastic syndrome in a patient with abdominal cancer. *Acta Derm Venereol* 1999;79:394.
12. Mork C, Kalgaard OM, Myrvang B, Kvernebo K. Erythromelgia in a patient with AIDS. *J Eur Acad Dermatol Venereol* 2000;14:498-500.
13. Pearn J. Neurology of ciguatera. *J Neurol Neurosurg Psychiatr* 2001;70:4-8.
14. Amato AA, Oaklander AL. Case records of the Massachusetts General Hospital. Case 16-2004. A 76-year-old woman with pain and numbness in the legs and feet. *N Engl J Med* 2004;350:2181-9.
15. Dabby R, Gilad R, Sadeh M, et al. Acute steroid responsive small-fiber sensory neuropathy: a new entity? *J Peripher Nerv Syst* 2006;11:47-52.
16. Wilder-Smith E. Steroid responsive small nerve fibre neuropathy: comment on article by Dabby, et al. *J Peripher Nerv Syst* 2006;11:172.
17. Mendell JR, Sahenk Z. Clinical practice. Painful sensory neuropathy. *N Engl J Med* 2003;348:1243-55.
18. Low VA, Sandroni P, Fealey RD, Low PA. Detection of small-fiber neuropathy by sudomotor testing. *Muscle Nerve* 2006;34:57-61.
19. Oh SJ, LaGanke C, Claussen GC. Sensory Guillain-Barré syndrome. *Neurology* 2001;56:82-6.
20. Seneviratne U, Gunasekera S. Acute small fibre sensory neuropathy: another variant of Guillain-Barre syndrome? *J Neurol Neurosurg Psychiatr* 2002;72:540-2.
21. Rauck RL, Naveira F, Speight KL, Smith BP. Refractory idiopathic erythromelgia. *Anesth Analg* 1996;82:1097-101.
22. Nathan A, Rose JB, Guite JW, et al. Primary erythromelgia in a child responding to intravenous lidocaine and oral mexiletine treatment. *Pediatrics* 2005;115:e504.
23. Chan MK, Tucker AT, Madden S, et al. Erythromelgia: an endothelial disorder responsive to sodium nitroprusside. *Arch Dis Child* 2002;87:229-30.
24. Kalgaard OM, Mork C, Kvernebo K. Prostacyclin reduces symptoms and sympathetic dysfunction in erythromelgia in a double-blind randomized pilot study. *Acta Derm Venereol* 2003;83:442-4.
25. Sandroni P, Davis MD. Combination gel of 1% amitriptyline and 0.5% ketamine to treat refractory erythromelgia pain: a new treatment option? *Arch Dermatol* 2006;142:283-6.
26. Hsieh ST, Lin WM. Modulation of keratinocyte proliferation by skin innervation. *J Invest Dermatol* 1999;113:579-86.
27. Oaklander AL, Cohen SP, Raju SV. Intractable postherpetic itch and cutaneous deafferentation after facial shingles. *Pain* 2002;96:9-12.
28. Drenth JP, Finley WH, Breedveld GJ, et al. The primary erythromelgia-susceptibility gene is located on chromosome 2q31-32. *Am J Hum Genet* 2001;68:1277-82.