

Refractory erythromelalgia of the ears: response to mexiletine

Alejandra C. Vivas, MD, Julia Escandon, MD, Robert S. Kirsner, MD, PhD*

Department of Dermatology and Cutaneous Surgery, University of Miami Miller School of Medicine, Miami, FL, USA

Received 19 October 2009

Abstract

Erythromelalgia is a rare condition characterized by burning pain, erythema, swelling, and increased temperature usually in the extremities. We present an unusual presentation of erythromelalgia of the ears in a patient who has been refractory to multiple therapies and in whom relief of symptoms was achieved with the use of mexiletine. A review of clinical presentation, pathophysiology, and therapeutic options are presented.

© 2011 Elsevier Inc. All rights reserved.

1. Introduction

Erythromelalgia (EM) is a rare disabling disorder of unclear etiology characterized by recurrent burning pain, erythema, and increased temperature of the affected area, typically feet and/or hands, but there are also reports of EM of the ears [1,2].

The associated pain is aggravated by warm environments and dependent position and is relieved by cold and frequent immersion into ice-cold water. This is a constant feature and is considered pathognomonic [3,4].

More common in men, EM may occur alone or be secondary to a myeloproliferative disorder, autoimmune disease, and associated with mercury poisoning, vasculitis, peripheral neuropathy, diabetes, hypertension, and drugs. Primary EM is an autosomal dominant neuropathic disorder involving a mutation in a voltage-gated sodium channel subunit $Na_v1.7$ that is expressed in nociceptive and sympathetic neurons [2]. EM is refractory to treatment. As an example in a review of data for 168 patients with EM at the Mayo clinic, patients had used 84 different types of medications [5].

In 2004, we presented a case report of refractory EM of the ears in this journal [1]. Since then, the patient has tried

multiple therapeutic options without response. Mexiletine was given, resulting in significant improvement of symptoms. We summarize our experience with this patient.

2. Patient presentation

A 58-year-old Hispanic man, with no significant comorbidities and an 8-year history of progressive burning pain and redness of the ears, has been seen in our service since 2003. He was diagnosed with primary EM.

Initially, the symptoms were sporadic, several episodes monthly, related to warm temperatures and physical activity, and had gradually worsened to the point of being constant and disturbing his sleep. He reported 9/10 pain and daily flares with pain, swelling, and redness. The use of cold water spray and avoidance of warm environments ameliorated his symptoms. On examination, both ears were involved, compromising the entire helix and antihelix, and he had pink to red, tender, and swollen plaques; no other areas were involved [1].

A biopsy of involved skin showed superficial and deep perivascular inflammation with prominent endothelial cells consistent with EM. Fungus and mycobacterium cultures were negative. An extensive laboratory analysis that included autoimmune workup came up negative or within normal limits except for serum qualitative cryoglobulin that was positive. Therefore, a workup to rule out viral hepatitis, multiple myeloma, Waldenström's macroglobulinemia, lymphoproliferative disorders, rheumatoid arthritis,

* Corresponding author. Department of Dermatology and Cutaneous Surgery, Epidemiology and Public Health, University of Miami Miller School of Medicine, 1600 NW 10th Avenue RMSB, Room 2023-A, Miami, FL 33136, USA. Tel.: +1 305 243 4472.

E-mail address: rkirsner@med.miami.edu (R.S. Kirsner).

Table 1

Therapies used in the treatment of EM in our patient

Antihistamines: diphenhydramine, fexofenadine, loratadine
Vasoactive drugs: calcium channel blockers (nifedipine, nicardipine, amlodipine), β -blockers (propranolol), nitrates (nitroglycerin ointment)
Nonsteroidal antiinflammatory drugs (acetylsalicylic acid, celecoxib, misoprostol)
Medications with effect on neurotransmitters: selective serotonin reuptake inhibitor (sertraline), Serotonin - norepinephrine reuptake inhibitors (venlafaxine), benzodiazepine (diazepam), tricyclic antidepressants (amitriptyline, doxepin), anticonvulsant (gabapentin), antipsychotics (risperidone)
Steroid analogs: prednisone, stanozolol, oxalondrone, ethisterone
Immunosuppressants: cyclosporin A, methotrexate, sirolimus
Antimicrobials: doxycycline, clarithromycin, minocyclin, dapsone
Other: magnesium sulfate, thalidomide, pentoxifylline, enoxaparine, isotretinoin, Melgatin (Berlin Homeo Products, Berlin, Germany) (herbal supplement), zonulin (novel human protein)
Topicals: fluocinonide, topical lidocaine, procaine + lidocaine, capsaicin, estrogen, ketamine 0.5% + amitriptyline 1% gel
Procedures: ganglion nerve block, acupuncture

and systemic lupus erythematosus was performed with negative results.

He has received multiple medications resulting in various responses ranging from transient and mild improvement to no response at all. Table 1 summarizes the medication that he used.

Mexiletine, 100 mg, 3 times a day was started on April 2009. After 3 weeks of treatment, the patient reported significant relief of symptoms. Reported side effects were mild and included headache, nausea, and heart burn.

An increase in the dose to 200 mg 3 times a day was attempted resulting in a dramatic improvement in pain and redness of his ears. However, the patient could not tolerate it because of a dose-dependent increase in the side effects.

At present, the patient is taking 100 mg of mexiletine 3 times a day with reduction in pain and disease flares.

3. Discussion

The optimal pharmacologic therapy in primary EM is still unknown. Because of its complex physiopathology, multiple drugs may be used in the treatment of EM. Case reports of

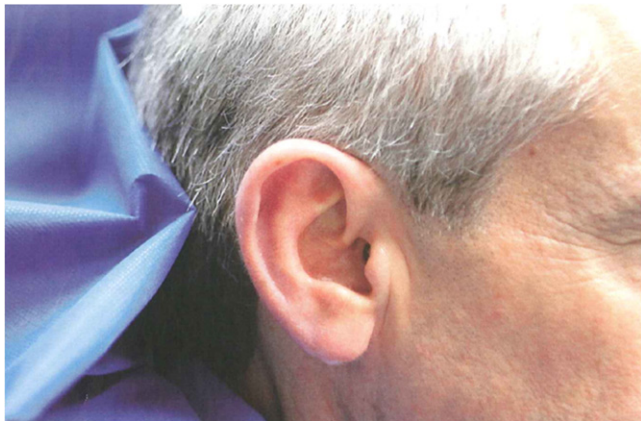


Fig. 1. Mild swelling and erythema of the ear after 3 months of treatment with mexiletine.

treatment with prostaglandins, venlafaxine, sertraline, fluoxetine, paroxetine, tramadol, gabapentin, prednisone, propranolol, benoxylamine hydrochloride, intravenous sodium nitroprusside, methylsergide, and cyproheptadine appear in the literature.

Aspirin has proved effective and is preferred in cases of EM-associated thrombocytopenia and polycythemia vera [6]. Nifedipine has been used to avoid reactive hyperemia due to its vasoconstrictive properties.

Other antidepressants such as amitriptyline and imipramine have been used with little improvement of symptoms.

Several topical agents have been used in the treatment such as capsaicin and lidocaine with variable response. In a study of 6 patients with severe EM, a documented improvement of more than 50% occur in 5 patients using a mixture of topical amitriptyline hydrochloride 1% and ketamine hydrochloride 0.5% applied 5 times daily [7].

Invasive approaches have been tried such as continuous epidural infusion of anesthetics and analgesics, nervous block, and sympathetic ganglion block.

Mexiletine is a class 1b antiarrhythmic agent; it is an oral derivative of lidocaine that blocks the sodium channels and shortens the action potential duration and decreases the frequency and stability of neuron firing involved in nociceptive pain processing [8]. Therefore, it has been used in neuropathic pain. Laboratory studies suggest a reduction in electrical current after exposure to mexiletine for the mutant sodium channel compared to the wild-type channels [9]. This is the rationale for the use of this drug in our patient.

Our patient showed sustained improvement of primary EM after treatment with mexiletine. After failure of multiple medications, the reported patient has an important and sustained relief of his symptoms with the use of mexiletine (Fig. 1).

References

- [1] Ramirez CC, Kirsner RS. A refractory case of erythromelalgia involving the ears. *Am J Otolaryngol* 2004;25:251-4.
- [2] Berk DR, Eisen AZ. Erythromelalgia of the ears: an unusual variant and response to therapy. *J Drugs Dermatol* 2008;7:285-7.

- [3] Iqbal J, Bhat MI, Charoo BA, et al. Experience with oral mexiletine in primary erythromelalgia in children. *Ann Saudi Med* 2009;29:316-8.
- [4] Creager MA, Loscalzo J. "Chapter 243. Vascular diseases of the extremities" (Chapter). Fauci AS, Braunwald E, Kasper DL, Hauser SL, Longo DL, Jameson JL, Loscalzo J: *Harrison's Principles of Internal Medicine*, 17e: <http://www.accessmedicine.com.medlib.med.miami.edu:2048/content.aspx?aID=2880274>.
- [5] Davis MD, O'Fallon WM, Rogers 3rd RS, et al. Natural history of erythromelalgia: presentation and outcome in 168 patients. *Arch Dermatol* 2000;136:406-9.
- [6] Cohen JS. Erythromelalgia: new theories and new therapies. *J Am Acad Dermatol* 2000;43:841-7.
- [7] Sandroni P, Davis MD. Combination gel of 1% amitriptyline and 0.5% ketamine to treat refractory erythromelalgia pain: a new treatment option. *Arch Dermatol* 2006;142:283-6.
- [8] Olschewsky A, Schnoebel-Ehehalt R, Li Y, et al. Mexiletine and lidocaine suppress the excitability of dorsal horn neurons. *Anesth Analg* 2009;109:258-64.
- [9] Choi JS, Zhang L, Dib-Hajj SD, et al. Mexiletine-responsive erythromelalgia due to a new Na(v)1.7 mutation showing use-dependent current fall-off. *Exp Neurol* 2009;216:383-9.