

## *Practical Pain Management*

# **MR Neurography: using peripheral nerve imaging as a pain diagnostic**

By Angie Drakulich

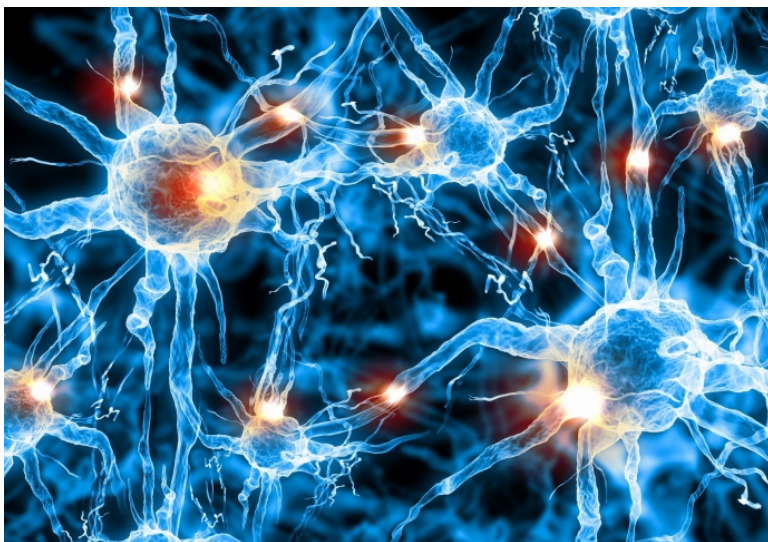
December 2018

Darryl B. Sneag, MD, and John A. Carrino, MD, of the Radiology and Imaging Department at New York's Hospital for Special Surgery (HSS) spoke to PPM about recent advances in magnetic resonance neurography (MRN) and how the technology is quickly becoming an essential resource for diagnosis of peripheral neuropathy. MR neurography is an advanced technique that enables visualization of the nerves beyond the spinal canal.

**PPM:** What technical advances have impacted the diagnostic ability of MR neurography?

**Dr. Sneag:** High-field (3 Tesla) strength scanners are now readily available across the country. Hardware development, including magnet strength and the coils placed on patients, has allowed us to obtain higher resolution to visualize the nerves. Ten years ago, you may have seen a mass along the course of the nerves, but now, not only can we look at individual nerves, but we can also see inside those nerves (ie, individual fascicular bundles or fascicles). Think of a coaxial cable, and cutting it open, to see all the individual wires inside. Some disease processes may not impact the whole nerve, but rather individual fascicles, so this advance is key in assessing certain inflammatory syndromes.

In addition, software development, such as novel pulse sequences, and quantitative techniques such as diffusion tensor imaging, can specifically help us to evaluate nerves and muscles. With routine imaging, we get simple types of contrast but in neurography, the software optimizes the contrast between the nerves and surrounding tissues. HSS has an institutional research agreement with General Electric Healthcare that has supported software and hardware developments related to MR neurography.



Magnetic resonance neurography (MRN) has seen some recent advances and has quickly become an essential resource for diagnosing peripheral neuropathy. (Source: 123RF)

**PPM:** Where do you see MRN having the greatest impact when it comes to pain assessment?

**Dr. Sneag:** We like to think of peripheral nerve imaging as a biomarker. Some complex syndromes, such as Parsonage-Turner Syndrome (also known as neuralgic amyotrophy), may have symptoms that overlap with other pathologies, such as cervical radiculopathy, and are thus sometimes difficult to diagnose. Biomarkers that can identify specific diseases and place patients into categories can better direct treatment. We want to know precisely what we are treating. An objective diagnosis through imaging can also help with longitudinal monitoring to see how nerves improve, or don't improve, over time.

**PPM:** How practical is the use of MRN today in terms of cost and availability?

**Dr. Sneag:** The costs and available technology of MRN are akin to most traditional MRIs. I will say that MRN requires some training beyond a traditional radiology residency. Familiarity with electrodiagnostic testing and understanding of peripheral nerve anatomy is also helpful for protocoling an exam to ensure that the clinical questions are answered.

**PPM:** What are you most excited about in regard to MRN?

**Dr. Sneag:** Many idiopathic peripheral neuropathies can be challenging to diagnose clinically, even by an experienced neurologist. Imaging of the nerves provides more objective information to localize the pain source(s) and to help guide treatment. In addition, we are using MRN weekly to assess for traumatic and iatrogenic injury. Sometimes, it is hard to know the severity of an injury and if a nerve will spontaneously recover prompting a watch-and-wait approach, or if there has been irreversible injury that may require surgery. Imaging, along with electrodiagnostics, can guide surgeons on when to operate and precisely localize the site, thereby reducing operative time and its associated potential morbidity.

**PPM:** What more is needed in the field of high-resolution medical imaging as it relates to pain management?

**Dr. Carrino:** A lot of physicians, including radiologists, are unaware of what the current capabilities of MRI are for looking at nerves. We need a better understanding across the healthcare field. Clinicians may refer for MR neurography if they are unable to find a diagnosis or to confirm a suspected diagnosis, and of course, for any peripheral neuropathy case.

**Dr. Sneag:** Overall, neurography is unique in that we are looking at tiny structures, sometimes sub-millimeter in size, and we do pretty well. But to push forward we need even higher spatial resolution. As a radiologist, you can only diagnose what you can see.

**PPM:** Perhaps foreseeing the growing importance of MRN, the Department of Radiology & Imaging at HSS has for several years supported the development of MR neurography, which Dr. Sneag now oversees. What do you want other healthcare providers to know about this growing subfield?

**Dr. Carrino:** In general, imaging is trying to become a commodity. Beyond interventional pain procedures, such as injections, clinicians need to better understand the growing technical capabilities of MRIs, including how to use machines and how to interpret the results. Not all readers are created equal and there are specialized protocols we use at HSS that require interaction with other multidisciplinary providers for optimal outcomes. This involves understanding imaging and understanding the disease process—that specific interaction is key. I would advise pain providers to seek out professionals who really know how to image the peripheral nerves rather than sending patients to the closest or most convenient location, which may not result in the most accurate information.